Diffuse Pulmonary Hemorrhage: Clues to the Diagnosis

John P. Lichtenberger III, MD, Subba R. Digumarthy, MD, Gerald F. Abbott, MD, Jo-Anne O. Shepard, MD, and Amita Sharma, MBBS

Diffuse pulmonary hemorrhage (DPH) refers to an uncommon but significant condition of bleeding into the alveolar space. Anemia and hemoptysis are important clinical features, but they may be absent. Although the radiographic and computed tomography findings are often varied and nonspecific, the imaging manifestations of pulmonary hemorrhage and the associated findings in the thorax often provide important diagnostic information that may lead to a specific diagnosis. DPH significantly influences patient management and has important prognostic implications. This review article explores the imaging findings in DPH and its differential diagnosis, highlighting important clues to this diagnosis and to its underlying etiology. DPH is an uncommon condition characterized by bleeding into the alveolar space that, when recognized on imaging, provides important diagnostic and prognostic information.

Introduction

Hemorrhage into the alveolar spaces is a final common event for a myriad of pulmonary diseases. Diffuse pulmonary hemorrhage (DPH) refers to an uncommon condition of bleeding into the alveolar space as a result of injury to the alveolar microcirculation. Histopathologically, disruption of the alveolar-capillary basement membrane results in the accumulation of red blood cells in the alveoli. Hemosiderin-laden macrophages collect in the affected portions of the lungs within 48-72 hours. When this process is detected on imaging, its appearance is not only varied but is also nonspecific. DPH should be considered in the setting of acute pulmonary parenchymal disease, and careful evaluation of imaging studies correlated with clinical data may lead to a specific diagnosis. Establishing the diagnosis of DPH has significant prognostic and therapeutic implications, underscoring the importance of recognizing this process.

From the Division of Thoracic Imaging and Intervention, Department of Radiology, Massachusetts General Hospital, Boston, MA.
Reprint requests: John P. Lichtenberger III, MD, Division of Thoracic Imaging and Intervention, Department of Radiology, Massachusetts General Hospital, 55 Fruit St, Founders 202, Boston, MA 02114. E-mail: John.lichtenberger@gmail.com.
Curr Probl Diagn Radiol 2014;43:128–139.
© 2014 Published by Mosby, Inc.
0363-0188/$36.00 + 0
http://dx.doi.org/10.1067/j.cpradiol.2014.01.002

Clinical Presentation

Two-thirds of patients with DPH present with hemoptysis.[1] Cough, dyspnea, and fever are other frequent symptoms. DPH, when not idiopathic, is a complication of other pulmonary diseases, which may determine the clinical presentation. For instance, Goodpasture syndrome may be preceded by an influenza-like illness and patients with Wegener granulomatosis (WG) may present with sinusitis.

Diagnostic Evaluation

The laboratory data suggesting a diagnosis of DPH include anemia, leukocytosis, and elevated levels of inflammatory markers. Specific disease markers seen in pulmonary renal syndromes include antiglomerular basement membrane (anti-GBM) antibody in Goodpasture syndrome and antineutrophil cytoplasmic antibody (ANCA) in WG. Lupus or antiphospholipid syndrome may be supported by evaluation of levels of complement fractions C3 and C4, anti–double-stranded DNA, and antiphospholipid antibodies.

A distinguishing feature of DPH is the increased diffusion capacity of the lung for carbon monoxide and decreased level of exhaled nitric oxide in pulmonary function testing. This is attributed to the absorption of carbon monoxide and nitric oxide by the

hemoglobin in alveolar blood. When pulmonary hemorrhage is chronic or recurrent, fibrosis may lead to a restrictive pattern of lung disease.[2] Pulmonary hemorrhage has also been associated with an obstructive lung disease similar to emphysema.[3]

Bronchoalveolar lavage (BAL) is an important component of the diagnosis of DPH. A BAL confirming DPH shows persistent or increasing aliquots of hemorrhage from lavage. This test is also useful in excluding infection or other alveolar-filling processes such as alveolar proteinosis. Although it is diagnostic of hemorrhage, BAL does not diagnose the underlying etiology of hemorrhage.[4] Ultimately, transbronchial or surgical biopsy may be required.

The imaging features of DPH depend on its chronicity. Acutely, imaging of the lung is normal in 20%-50% of cases.[5] When present, the radiographic manifestations of acute pulmonary hemorrhage include airspace opacities with a central and basilar predominance and sparing the costophrenic angles. On computed tomography (CT) scans, these abnormalities correspond to patchy ground-glass opacities without significant interlobular septal thickening (Fig 1A).

In the subacute phase, typically within 48 hours, interlobular and intralobular interstitial thickening develop. Septal thickening may occur while ground-glass opacities persist, resulting in a crazy-paving pattern on CT images (Fig 1B). Clearing of acute airspace opacities and septal thickening usually occurs within 2 weeks in a monophasic episode of pulmonary hemorrhage. When hemorrhage is chronic and recurrent, pulmonary fibrosis develops with regions of architectural distortion and areas of lobular sparing in a background of septal thickening and fibrosis (Fig 1C).

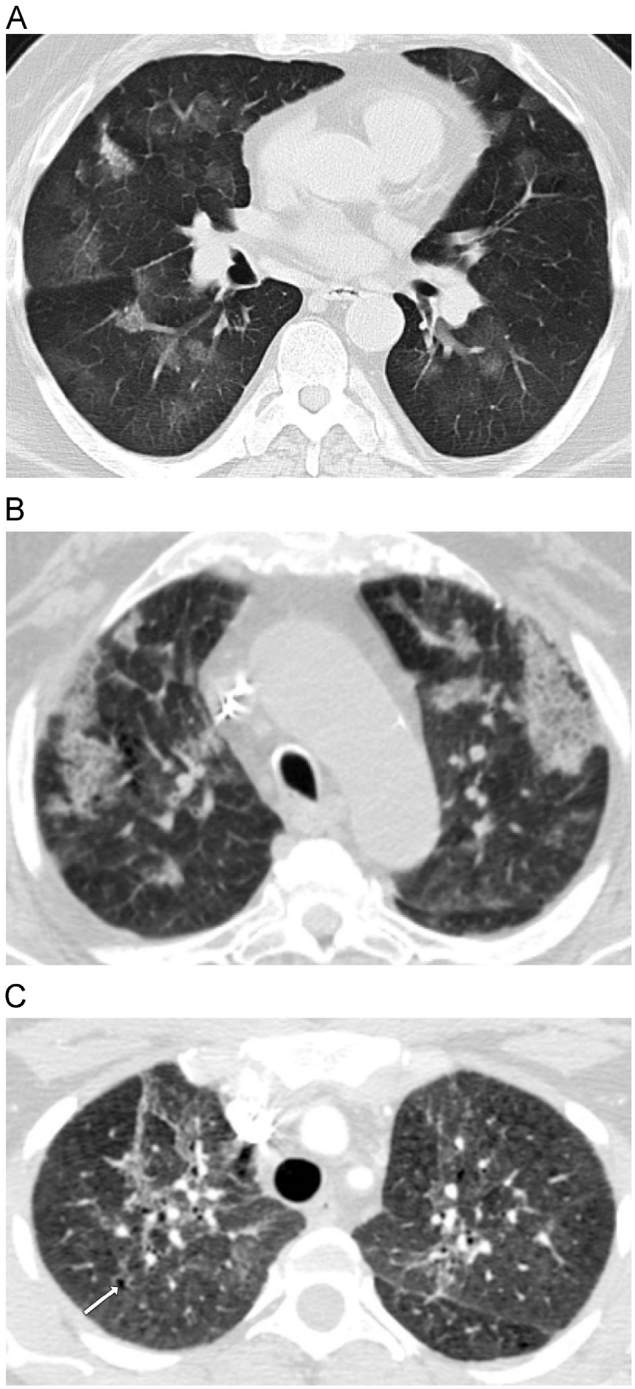

FIG 1. Axial CT image (A) shows bilateral patchy ground-glass opacities in a 52-year-old patient with antiphospholipid syndrome and acute hemoptysis. Ground-glass opacities are typical in acute pulmonary hemorrhage. Axial CT image (B) shows bilateral ground-glass opacities with superimposed interlobular septal thickening in this patient with subacute pulmonary hemorrhage. Axial CT image (C) shows bilateral upper lobe linear opacities with associated traction bronchiectasis (arrow) indicating fibrosis in this patient with Goodpasture syndrome and chronic pulmonary hemorrhage.

Causes of DPH

Most cases of DPH are secondary to an underlying disease affecting the lung (Table 1).

These diseases can be categorized clinically into pulmonary renal syndromes, vasculitides, autoimmune disease, and those secondary to drug effect. Rarely, hemorrhage into the alveolar space is idiopathic. The relative frequency of causes of DPH has not been prospectively studied. However, a study of 34 pathologically proven cases of DPH diagnosed on histopathology showed WG to be the most common cause, followed by Goodpasture syndrome, idiopathic pulmonary hemorrhage, and collagen vascular disease.[6]

TABLE 1. Etiology of diffuse pulmonary hemorrhage

Vasculitis	Pulmonary renal syndromes	Autoimmune	Drug effect	Idiopathic pulmonary hemosiderosis
Wegener granulomatosis	Goodpasture syndrome	Systemic lupus erythematosus	Anticoagulation	
Churg-Strauss syndrome	Connective tissue diseases	Antiphospholipid antibody syndrome	Drug-induced thrombocytopenia	
Microscopic polyangiitis	IgA nephropathy		Unknown mechanism	

Wegener Granulomatosis

WG is a multisystemic necrotizing vasculitis most commonly affecting white patients aged 40-50 years. A triad of upper airway disease consisting of sinusitis, pulmonary disease, and renal disease may be present in these patients. Clinical features include a saddle nose deformity, hemoptysis, cough, and fever. In the Etanercept Trial, DPH was a complication of WG in 25% of patients, and these patients were categorized as severely affected. These patients were more frequently older men.[7]

The most common imaging appearance of WG is the presence of lung nodules and masses, occurring in 40%-70% of affected patients. These nodules are bilateral and have no zonal predilection.[8] They may cavitate and demonstrate an adjacent halo of ground-glass opacity on CT images.[9] Airspace opacities occur in approximately 50% of patients.[10] When consolidation and ground-glass opacities are diffuse, this usually represents DPH (Fig 2).[8] Arteriolar vasculitis may result in mosaic perfusion. Airway involvement is a late complication that may result in focal or diffuse stenosis, which occurs in 20% of patients. In the setting of large airway disease, subglottic tracheal involvement is common.

c-ANCA serum antibody is present in most patients with WG, and rising titers may predict active disease or relapse.[11] Histopathology following tissue sampling is confirmatory of the diagnosis and shows parenchymal necrosis, necrotizing vasculitis characterized by eccentric transmural infiltrate of mononuclear cells, and necrotizing granulomatous inflammation.[12,13] Treatment typically involves administration of cyclophosphamide in combination with corticosteroids. Methotrexate or azathioprine may be used for maintenance therapy and in less severe disease states. Rituximab and early plasma exchange may have limited roles in the treatment of WG.[14,15] Patients with ANCA-associated small vessel vasculitis complicated by pulmonary hemorrhage benefit from plasmapheresis.[16] Although the exact mechanism of benefit is unknown, the effect is attributed to removal of ANCA serum antibody, which is known to be cytotoxic and causally associated with small vessel vasculitis.[16]

Goodpasture Syndrome

Goodpasture syndrome is characterized by a type II antibody reaction to GBM, resulting in a combination of glomerulonephritis and pulmonary hemorrhage. It is a rare disease, occurring in 0.5 people per million per year.[17] The distribution is bimodal, with young white men most commonly affected, followed by older women. Renal disease is often the predominant disease manifestation in the latter demographic, and 20%-40% of all patients present with isolated renal involvement. Lung disease in isolation is rare. Patients with Goodpasture syndrome often have a history of recent viral infection and present with severe shortness of breath, cough, and hemoptysis. They may have anemia, renal failure, hematuria, and proteinuria.

Imaging manifestations of Goodpasture syndrome in the lung are typical for pulmonary hemorrhage, characterized by diffuse ground-glass opacity in the acute phase progressing to pulmonary fibrosis when chronic. Pleural effusions are uncommon (Fig 3). The diagnosis of Goodpasture syndrome is made by enzyme-linked immunosorbent assay or radioimmunoassay for anti-GBM antibodies. Treatment typically involves corticosteroids and immunosuppressants.[18] Plasmapheresis may be employed to remove anti-GBM antibodies. End-stage renal failure may necessitate renal transplant.

Idiopathic Pulmonary Hemosiderosis

Idiopathic pulmonary hemosiderosis (IPH) is a diagnosis of exclusion, made when pulmonary hemorrhage is present without associated findings such as

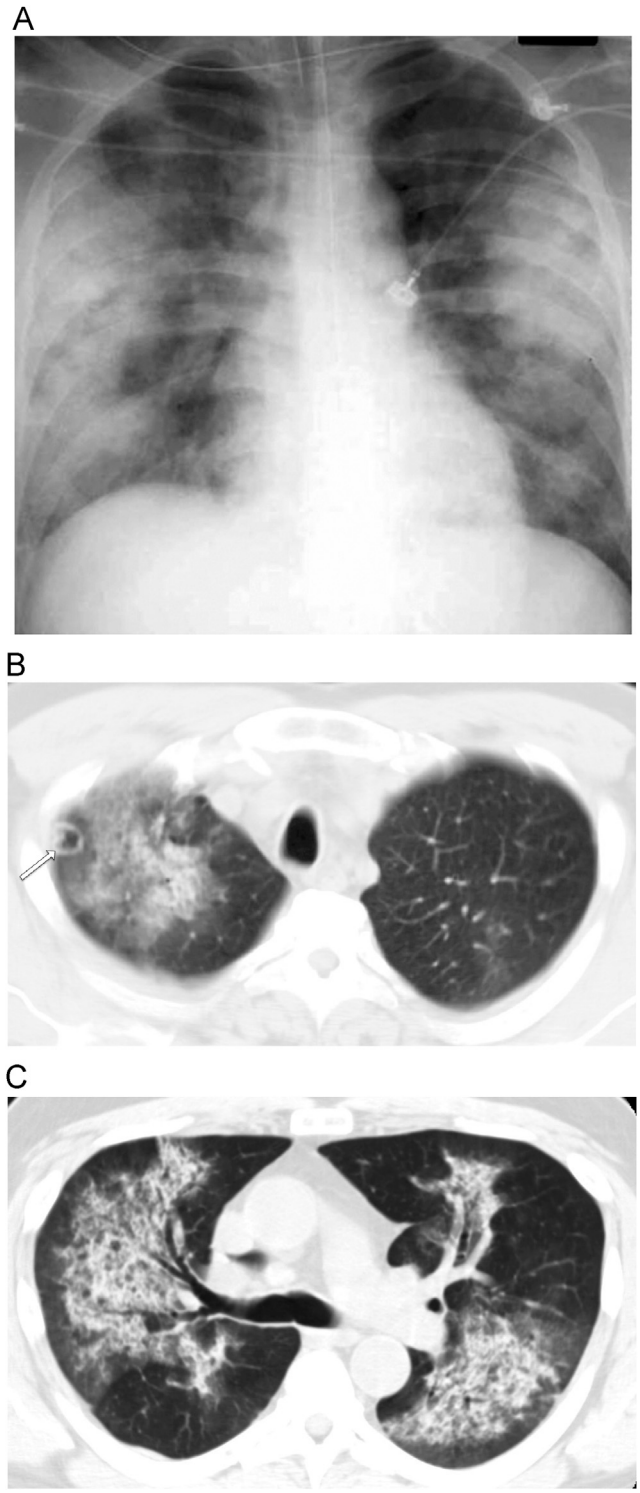

FIG 2. Frontal radiograph (A) shows bilateral, symmetric consolidations in a 40-year-old patient with respiratory distress and history of Wegener granulomatosis. Axial CT images (B and C) in a different patient with Wegener granulomatosis and hemoptysis show a cavitary nodule (arrow) in the right upper lobe, ground-glass opacities, and consolidations consistent with pulmonary hemorrhage.

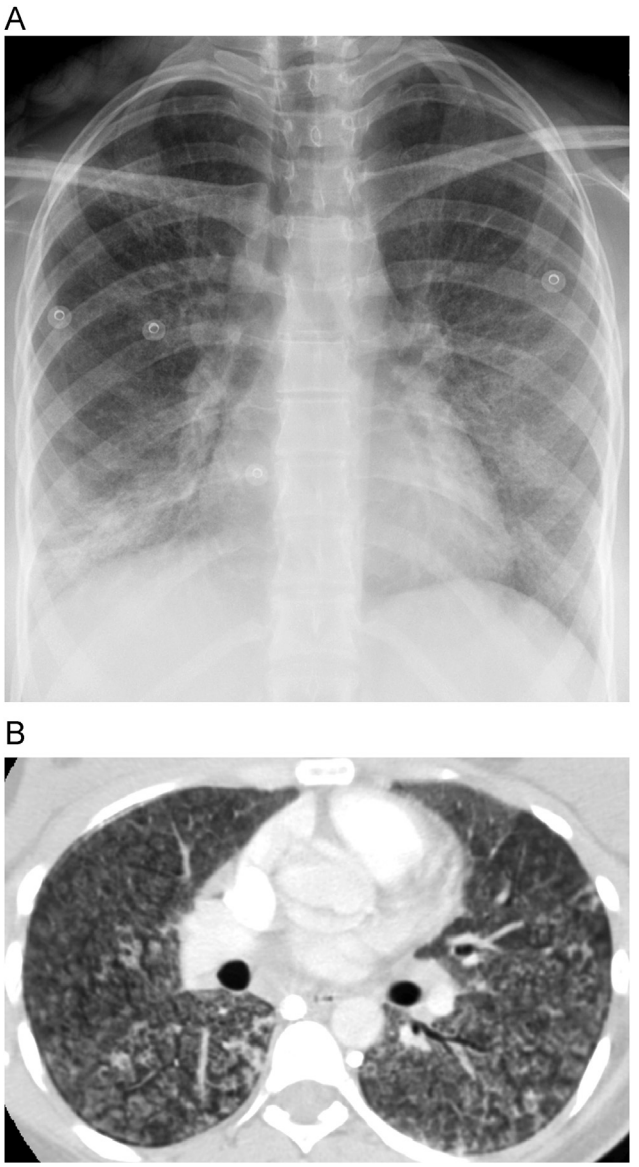

FIG 3. Frontal radiograph (A) shows diffuse hazy opacities without pleural effusion. The cardiac silhouette is not enlarged. Bronchoalveolar lavage showed multiple aliquots of blood in this patient with Goodpasture syndrome. Axial CT image (B) shows diffuse centrilobular ground-glass opacities in a different patient with Goodpasture syndrome and hemoptysis.

glomerulonephritis. Pulmonary manifestations are indistinguishable from Goodpasture syndrome clinically, although renal disease is absent.[19] This disease typically occurs in children and young adults, with an incidence of 0.24 persons per million.[20] It is more frequent in men older than 10 years (M:F = 2:1).[20] The clinical presentation includes hemoptysis, dyspnea, and iron deficiency anemia. Recurrent hemorrhage leads to

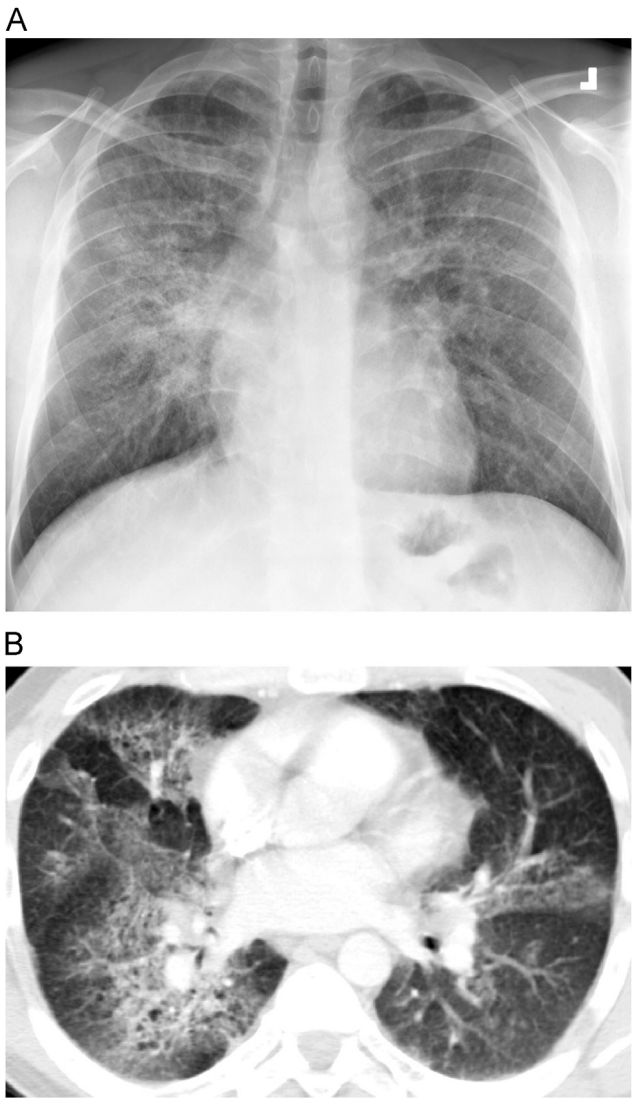

FIG 4. Frontal radiograph (A) shows predominant central and upper lobe patchy opacities in a 30-year-old man with idiopathic pulmonary hemosiderosis. Axial CT image (B) shows multifocal ground-glass opacities and architectural distortion consistent with chronic pulmonary hemorrhage.

hemosiderin deposition and an associated brownish discoloration of the lung on gross pathology. Criteria on histopathology include erythrocytes in the distal airways and alveoli, hemosiderin-laden macrophages, and lack of other underlying pulmonary disease or infection.[21]

In some ways, IPH is the prototypical example of pulmonary hemorrhage, in that, radiologically, the disease manifestations are solely related to pulmonary hemorrhage by definition. Acutely, ground-glass opacities are diffuse. Occasionally, there are centrilobular nodular opacities. The chronic appearance is that of pulmonary fibrosis (Fig 4). Although magnetic resonance imaging is not routinely used to evaluate pulmonary hemorrhage, paramagnetic effects of iron may result in low signal intensity within the lung.[22] Patients with IPH often respond to immunosuppressant therapy, which may support an underlying autoimmune etiology.

Churg-Strauss Syndrome

Churg-Strauss syndrome is an idiopathic allergic granulomatosis affecting small vessels and causing necrotizing vasculitis. This is distinguished from polyarteritis nodosa by the presence of pulmonary disease and peripheral eosinophilia. Churg-Strauss syndrome is seen almost exclusively in asthmatics, and the average age at onset is between 40 and 50 years. Patients present with asthma, neuropathy, sinusitis, and eosinophilia.

On CT scans, peripherally distributed areas of consolidation and alveolar opacities are present, which typically represent eosinophilic infiltration.[23] These opacities may be transient and fleeting and precede systemic vasculitis (Fig 5). Pulmonary nodules and reticulonodular opacities are less common. Unlike most causes of pulmonary hemorrhage, pleural effusions are present in 30% of cases.[24]

The diagnosis of Churg-Strauss syndrome is supported by criteria from the American College of Rheumatology that include asthma, eosinophilia, neuropathy, pulmonary disease, and sinus disease. This disease may be associated with c-ANCA (40%-75%) or perinuclear ANCA. Biopsy reveals extravascular eosinophilic infiltration and small vessel necrosis. The treatment typically involves systemic corticosteroids and adjuvant cyclophosphamide, and pulmonary lesions may completely regress after successful therapy.

Microscopic Polyangiitis

Microscopic polyangiitis (MPA) is a small vessel vasculitis thought to be on a spectrum with WG, though upper respiratory tract involvement and granuloma formation are absent in MPA. Perinuclear-ANCA directed against neutrophil myeloperoxidase is identified serologically.[25] This is a rare disease typically occurring in middle-aged men, with an annual incidence of 3-4 per million individuals.[25] Focal segmental glomerulonephritis occurs in all patients and capillaritis results in pulmonary hemorrhage. Patients present with constitutional symptoms, rash, dyspnea, and hemoptysis (11%).[25] DPH occurs

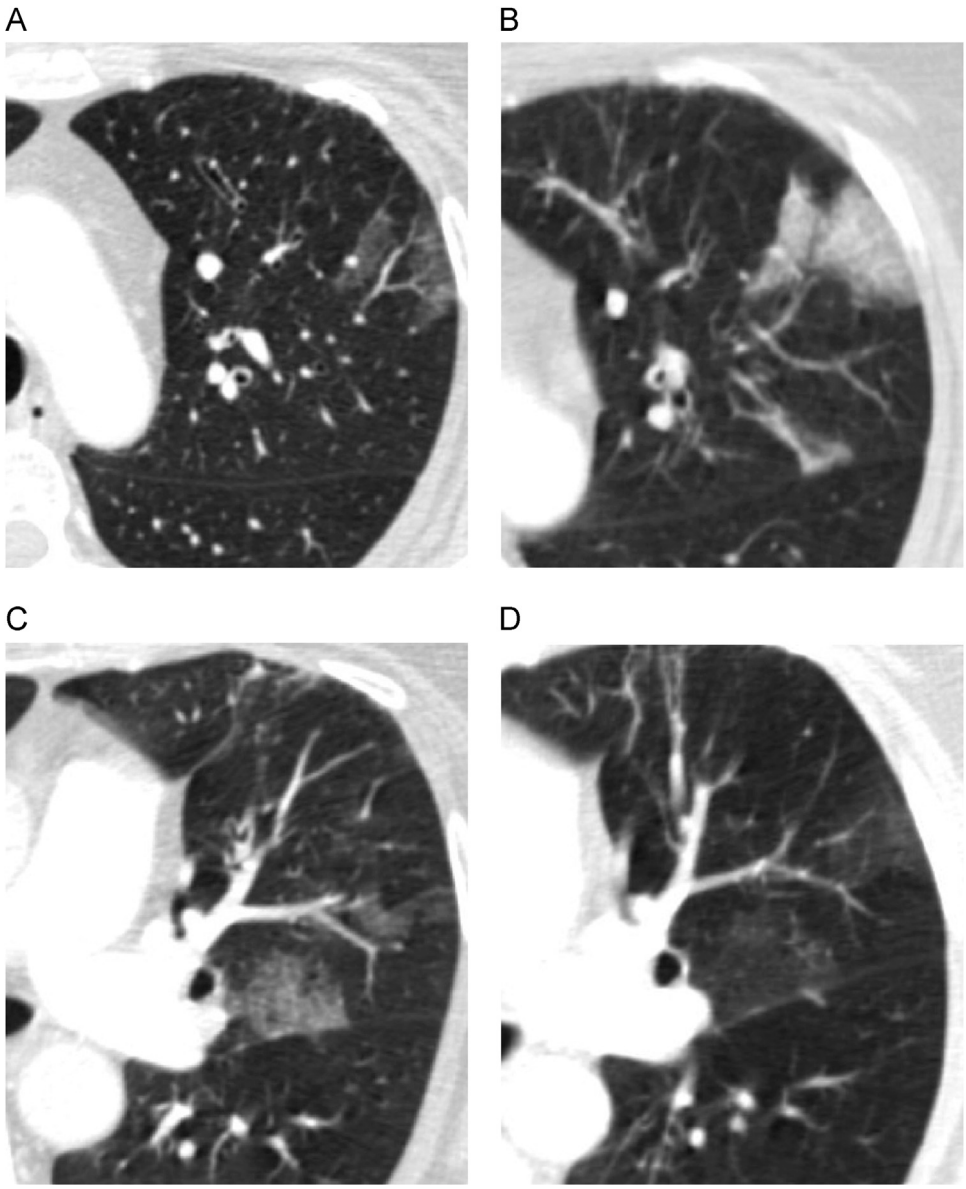

FIG 5. Axial CT images taken at presentation (A and C) and a week later (B and D) show asynchronous peripheral ground-glass opacities in a patient with Churg-Strauss syndrome.

in approximately 30% of patients with MPA and has a significant effect on the mortality of this disease. Approximately 30% of patients with MPA who have acute DPH die of respiratory failure, and the 5-year survival of patients who develop DPH is only 68%.[26]

Imaging findings in MPA are nonspecific, with pulmonary hemorrhage presenting as ground-glass opacities with septal thickening (Fig 6).

Histologic findings in MPA include necrotizing arteritis, particularly of small vessels (arterioles, venules, and capillaries). Autoantibodies are not a common finding. Treatment in the acute phase involves administration of oral prednisone, cyclophosphamide, and plasmapheresis. When pulmonary disease is severe and complicated by DPH, recombinant factor VIIa has been used to augment thrombin at the hemorrhagic sites.[27]

Systemic Lupus Erythematosus

Systemic lupus erythematosus (SLE) is an immune complex–mediated microvasculitis. It is the most common collagen vascular disease associated with DPH, although pulmonary hemorrhage occurs in only 2% of patients.[1] Incidence rates of SLE are higher among African American and Latin Americans than in

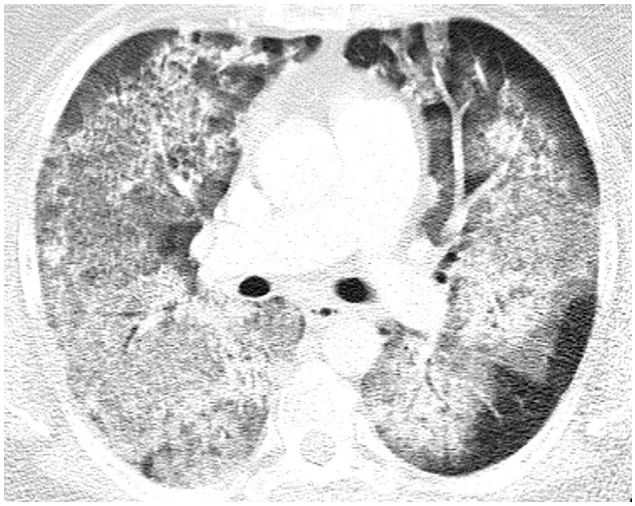

FIG 6. Axial CT image shows bilateral, confluent ground-glass opacities in this patient with microscopic polyangiitis.

other ethnic groups, and prevalence is highest among females between the ages of 14 and 64. Patients may present with constitutional symptoms, a malar rash, and pleurisy. Hemoptysis may be massive in cases of SLE complicated by DPH.[28] However, it is important to note that even in cases of dropping hematocrit and radiographic opacities, hemotpysis is not necessarily present in cases of DPH.[29]

Although the imaging findings of DPH in SLE are nonspecific (Fig 7), the other manifestations of this disease may provide clues to the diagnosis. Pleural effusions, uncommon in most causes of pulmonary hemorrhage, are present bilaterally in 50% of these patients.[30] Respiratory muscle dysfunction is present in up to 25% of patients with SLE, which may manifest as an elevated hemidiaphragm and decreased lung volumes.[30] Cardiomegaly may be a result of SLE myocarditis or secondary to other systemic disease such as uremia.[31] Pericardial effusions may complicate SLE and lead to tamponade.[32]

Serum antinuclear autoantibodies and antibodies to double-stranded DNA are important diagnostic markers for SLE. The American College of Rheumatology has established clinical criteria for the diagnosis of SLE, including malar or discoid rash, nonerosive arthritis, pleuritis, renal disorders, and neurologic disorders.[33,34] DPH is considered a severe and emergent complication of SLE and is treated with high-dose corticosteroids and cytotoxic therapy. The mortality rate in patients with SLE who experience DPH is approximately 50%.[1]

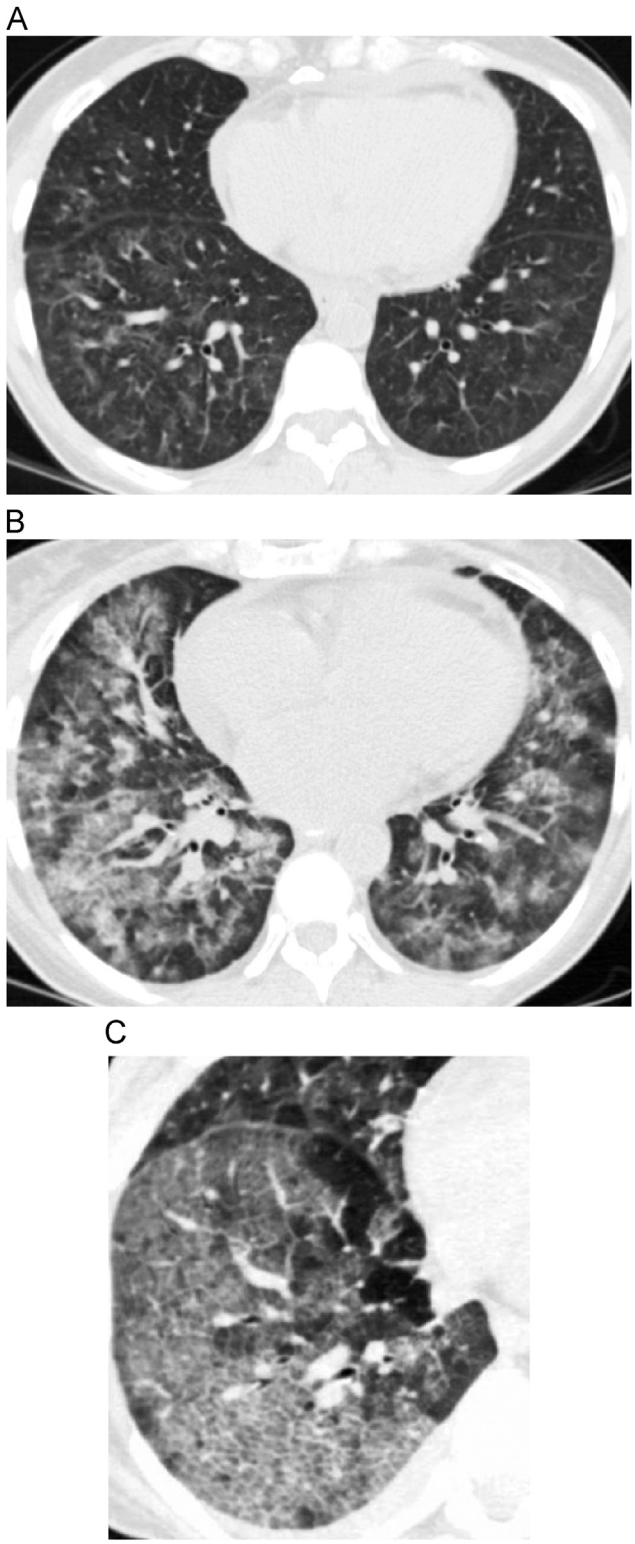

FIG 7. Axial CT images show patchy ground-glass opacities (A) that progress over 1 month to regions of consolidation and ground-glass opacities (B) in a 52-year-old woman with systemic lupus erythematosus. (C) Axial CT image in a different patient with SLE and hemoptysis shows ground-glass opacity with interlobular septal thickening.

TABLE 2. Drugs associated with diffuse pulmonary hemorrhage

Amiodarone
Propylthiouracil
Abciximab
Anticoagulant therapy
Nitrofurantoin
Phenytoin
Penicillamine*
Carbimazole*

*Can rarely cause a pulmonary renal syndrome similar to Goodpasture syndrome.

Drug Effect

Among drug toxicities resulting in pulmonary hemorrhage, anticoagulants and drug-induced thrombocytopenia are the leading causes (Table 2). Medications such as penicillamine and carbimazole may rarely cause a pulmonary renal syndrome similar to Goodpasture syndrome.[35] DPH secondary to anticoagulation is more common with thrombolytics than in Coumadin therapy. Clinically, bleeding from other sites may be a diagnostic clue. Treatment consists of platelet transfusion and administration of fresh frozen plasma, although dialysis may be required in life-threatening situations.

DPH is a common complication of smoking crack cocaine and is present at autopsy in 85% of patients who die of overdose.[36,37] Although *crack lung* refers to an acute pulmonary syndrome occurring within 48 hours of inhaling cocaine, DPH in patients who smoke crack cocaine may also be chronic and clinically occult. On imaging, pulmonary hemorrhage is typically bilateral, multifocal, and predominantly composed of ground-glass opacity in the acute setting (Fig 8).[38]

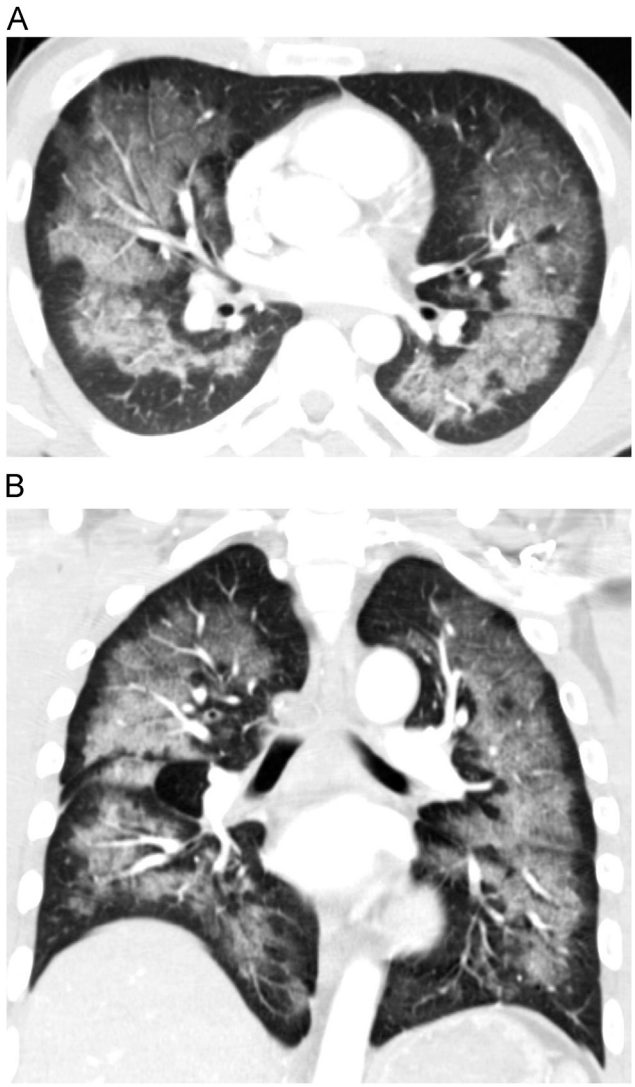

FIG 8. Axial (A) and coronal reformatting (B) CT images show geographic ground-glass opacities with peripheral sparing in a 37-year-old man with hemoptysis and recent cocaine use.

Bone Marrow Transplant

DPH in stem cell transplant recipients is a noninfectious complication of unclear pathophysiology seen in the early posttransplant period, occurring with a frequency of approximately 5%.[39] Onset of symptoms is usually within the first 30 days after transplant, typically consisting of hypoxia, dyspnea, and cough. Hemoptysis may be absent.[39] Diagnostic criteria have been established for DPH in stem cell transplant recipients, including widespread alveolar injury and absence of infection. BAL is an important component of the diagnostic criteria, supporting the diagnosis of DPH when there are 3 separate progressively bloodier samples, 20% or more hemosiderin-laden macrophages, and at least 30% of alveolar surfaces demonstrating blood.[39]

Initial radiographic findings are central to lower lung zone predominant ground-glass opacities, which rapidly progress over the first 6 days after presentation into a diffuse pattern (Fig 9).[40]

Treatment of DPH in bone marrow transplant patients typically involves corticosteroids, platelet administration, and supportive care.[41] The mortality rate when bone marrow transplant is complicated by DPH approaches 80%.[42]

Chronic Pulmonary Venous Hypertension

Chronic pulmonary venous hypertension is often secondary to severe mitral valve disease and regurgitation (Fig 10).[43] Longstanding venous hypertension

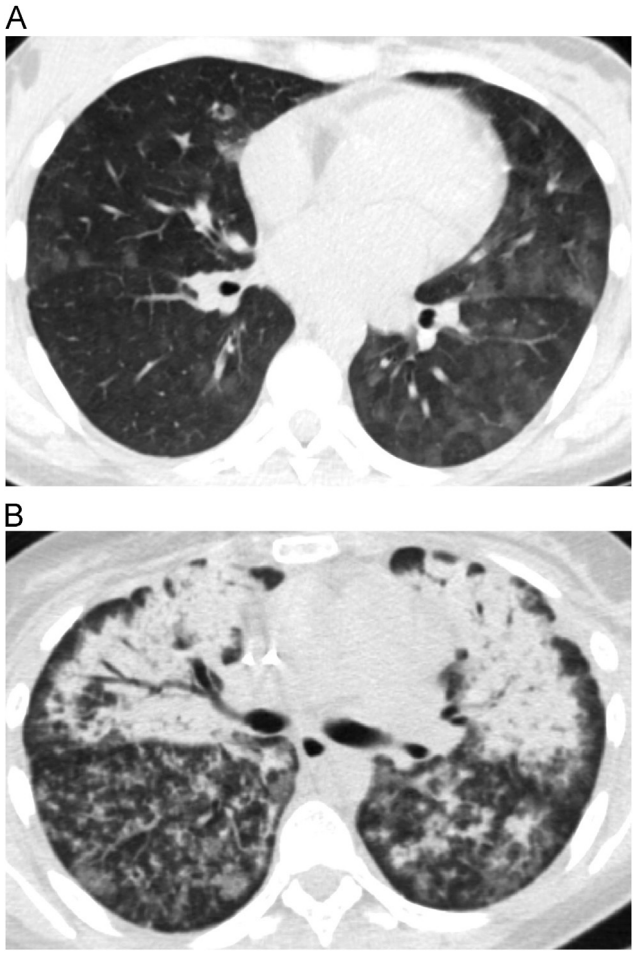

FIG 9. Axial CT images taken 1 week (A) and 3 weeks (B) after bone marrow transplant in a 22-year-old woman with acute myelogenous leukemia. Ground-glass opacities become consolidative opacities as respiratory status deteriorates.

and disruption of the alveolar-capillary membrane may lead to pulmonary hemorrhage when other causes have been excluded. Rupture of submucosal bronchial varices may be an alternative source of hemorrhage in these patients.

Differential Diagnosis and Diagnostic Clues

When pulmonary hemorrhage is suspected, either clinically or radiologically, it is important to differentiate localized pulmonary hemorrhage from DPH.[44] Bronchiectasis, tumors, and some infections can result in focal aspiration of blood which may be indistinguishable from alveolar bleeding. Recognizing pulmonary hemorrhage as truly diffuse and not associated with focal pathology will change the clinical and diagnostic approach.

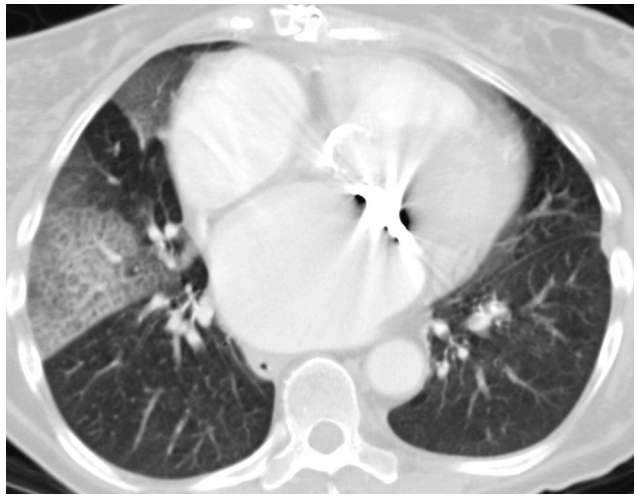

FIG 10. Axial CT image shows ground-glass opacities in the right upper and middle lobes with interlobular septal thickening consistent with pulmonary hemorrhage in a 71-year-old woman with rheumatic heart disease, mitral valve replacement, and chronic pulmonary venous hypertension.

The differential diagnosis of imaging findings in DPH most broadly overlaps with pulmonary edema and infectious etiologies (Fig 11). When considering pulmonary edema, several distinguishing features may be helpful. Cardiogenic pulmonary edema is typically characterized by cardiomegaly and rapid change in radiologic appearance. Alveolar opacities in DPH resolve more slowly over the course of days. Pleural

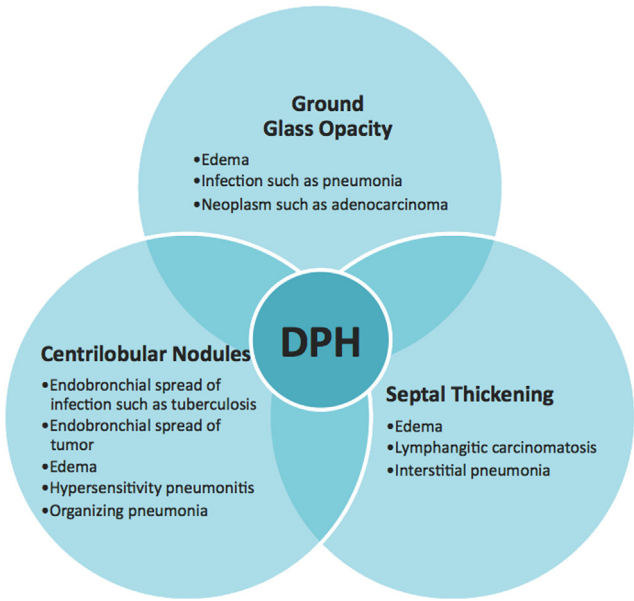

FIG 11. Differential diagnosis of findings in diffuse pulmonary hemorrhage. (Color version of figure is available online.)

effusions are common in most causes of pulmonary edema, whereas this feature is uncommon in DPH. Finally, the findings in edema are typically gravity dependent. When considering infectious etiologies, clinical presentation and laboratory data such as fever, cough, and leukocytosis may support this alternative diagnosis. However, there is considerable overlap with DPH in this clinical presentation. In these cases, BAL may be necessary.

The diagnosis of DPH is often entertained when thoracic imaging studies are performed in 1 of 2 circumstances. First, when patients with a known systemic disorder such as Goodpasture syndrome or SLE present with respiratory symptoms, DPH may be higher on the list of diagnostic considerations when imaging findings follow the expected temporal evolution of hemorrhage. That is, ground-glass opacities in a central and lower lung zone distribution evolve into septal thickening in 48-72 hours and the imaging features resolve by 7-14 days. If this process is repeated or chronic, fibrosis may be present.

Alternatively, when the clinical suspicion for DPH is high but an underlying diagnosis has not been established, imaging findings compatible with hemorrhage may be categorized into a favored disease with the aid of demographics, associated imaging findings, and clinical data that may have been overlooked. Demographically, idiopathic pulmonary hemorrhage usually occurs in children and young adults, Goodpasture syndrome is relatively rare in women (male: female is 9:1), and SLE is less common in men (female:male is 2:1). Associated imaging findings that may support an etiology of hemorrhage (Table 3). Finally, a review of clinical data may reveal a history of asthma and neuropathy to suggest Churg-Strauss syndrome, a medication known to predispose to pulmonary hemorrhage such as anticoagulation or drug-induced thrombocytopenia, or renal disease indicating pulmonary renal syndromes or severe uremia.

TABLE 3. Clues to diagnosing the cause of diffuse pulmonary hemorrhage

Cause of DPH	Clues to the diagnosis
Wegener granulomatosis	Cavitary nodules Tracheal involvement
Goodpasture syndrome	Glomerulonephritis
SLE	Pleural or pericardial effusions or both
Churg-Strauss syndrome	Transient and peripheral opacities
Chronic pulmonary venous hypertension	Left atrial enlargement Mitral valve pathology
Amiodarone toxicity	Hyperattenuating consolidation

Management

Treatment of DPH is based on the underlying etiology. Corticosteroids, immunosuppressants (eg, cyclophosphamide), and plasmapheresis are used in immune complex and inflammatory diseases. High doses of corticosteroids may be used in DPH related to bone marrow transplant.[45] In idiopathic pulmonary hemorrhage, early evidence suggests that azathioprine in combination with corticosteroids might be the best therapeutic regimen.[46]

The prognosis of DPH is also dependent on the underlying disease and therefore highly variable. IPH has a 5-year survival rate of 86% with therapy.[45] When complicated by DPH, SLE has a mortality rate of 50%.[1] If DPH is untreated in WG, the mortality rate reaches 90%.[47] These prognostic implications emphasize the importance of recognizing the imaging features of DPH.

Summary

DPH is a challenging but important diagnosis for the radiologist to incorporate into a differential diagnosis. Although the individual imaging features of ground-glass opacity and septal thickening are nonspecific, key distinguishing features of DPH include the distribution of these findings, the temporal evolution of hemorrhage, and the radiologic manifestations of underlying pulmonary disease that predisposes to hemorrhage. Imaging maintains a central role in arriving at the diagnosis of DPH.

Appropriately raising the suspicion for DPH and confirming this diagnosis when clinically suspected have a significant therapeutic and prognostic impact.

REFERENCES

1. Zamora MR, Warner ML, Tuder R, et al. Diffuse alveolar hemorrhage and systemic lupus erythematosus. Clinical presentation, histology, survival, and outcome. Medicine (Baltimore) 1997;76(3):192-202.
2. Schwarz MI, Mortenson RL, Colby TV, et al. Pulmonary capillaritis. The association with progressive irreversible airflow limitation and hyperinflation. Am Rev Respir Dis 1993;148(2):507-11.
3. Hunt DP, Weil R, Nicholson AG, et al. Pulmonary capillaritis and its relationship to development of emphysema in hypocomplementaemic urticarial vasculitis syndrome. Sarcoidosis Vasc Diffuse Lung Dis 2006;23(1):70-2.

4. Lara AR, Schwarz MI. Diffuse alveolar hemorrhage. Chest 2010;137(5):1164-71.
5. Albelda SM, Gefter WB, Epstein DM, et al. Diffuse pulmonary hemorrhage: a review and classification. Radiology 1985;154(2):289-97.
6. Travis WD, Colby TV, Lombard C, et al. A clinicopathologic study of 34 cases of diffuse pulmonary hemorrhage with lung biopsy confirmation. Am J Surg Pathol 1990;14(12):1112-25.
7. Stone JH, Wegener's Granulomatosis Etanercept Trial Research Group; Limited versus severe Wegener's granulomatosis: baseline data on patients in the Wegener's Granulomatosis Etanercept Trial. Arthritis Rheum 2003;48(8): 2299-309.
8. Cordier JF, Valeyre D, Guillevin L, et al. Wegener's granulomatosis: a clinical and imaging study of 77 cases. Chest 1990;97:906-12.
9. Lee KS, Kim TS, Fujimoto K, et al. Thoracic manifestation of Wegener's granulomatosis: CT findings in 30 patients. Eur Radiol 2003;13:43-51.
10. Sheehan RE, Flint JDA, Müller NL. Computed tomography features of thoracic manifestations of Wegener granulomatosis. J Thorac Imaging 2003;18:34-41.
11. van der Woude FJ, Rasmussen N, Lobatto S, et al. Autoantibodies against neutrophils and monocytes: tool for diagnosis and marker of disease activity in Wegener's granulomatosis. Lancet 1985;1(8426):425-9.
12. Travis WD, Colby TV, Koss MN, et al. Nonneoplastic Disorders of the Lower Respiratory Tract. Washington, DC: Armed Forces Institute of Pathology, 2002:233-64.
13. Travis WD, Carpenter HA, Lie JT. Diffuse pulmonary hemorrhage. An uncommon manifestation of Wegener's granulomatosis. Am J Surg Pathol 1987;11(9):702-8.
14. Keogh KA, Ytterberg SR, Fervenza FC, et al. Rituximab for refractory Wegener's granulomatosis: report of a prospective, open-label pilot trial. Am J Respir Crit Care Med 2006;173(2):180-7.
15. Sugimoto T, Deji N, Kume S, et al. Pulmonary-renal syndrome, diffuse pulmonary hemorrhage and glomerulonephritis, associated with Wegener's granulomatosis effectively treated with early plasma exchange therapy. Intern Med 2007;46(1):49-53.
16. Klemmer PJ, Chalermskulrat W, Reif MS, et al. Plasmapheresis therapy for diffuse alveolar hemorrhage in patients with small-vessel vasculitis. Am J Kidney Dis 2003;42(6): 1149-53.
17. Savage CO, Pusey CD, Bowman C, et al. Antiglomerular basement membrane antibody mediated disease in the British Isles 1980-4. Br Med J 1986;292(6516):301-4.
18. Levy JB, Turner AN, Rees AJ, et al. Long-term outcome of anti-glomerular basement membrane antibody disease treated with plasma exchange and immunosuppression. Ann Intern Med 2001;134(11):1033-42.
19. Ioachimescu OC, Sieber S, Kotch A. Idiopathic pulmonary haemosiderosis revisited. Eur Respir J 2004;24(1):162-9.
20. Kjellman B, Elinder G, Garwicz S, et al. Idiopathic pulmonary haemosiderosis in Swedish children. Acta Paediatr Scand 1984;73(5):584-8.
21. Soergel KH, Sommers SC. Idiopathic pulmonary hemosiderosis and related syndromes. Am J Med 1962;32(4):499-511.
22. Rubin GD, Edwards DK 3rd, Reicher MA, et al. Diagnosis of pulmonary hemosiderosis by MR imaging. Am J Roentgenol 1989;152(3):573-4.
23. Jeong YJ, Kim KI, Seo IJ, et al. Eosinophilic lung diseases: a clinical, radiologic, and pathologic overview. Radiographics 2007;27(3):617-37.
24. Erzurum SC, Underwood GA, Hamilos DL, et al. Pleural effusion in Churg-Strauss syndrome. Chest 1989;95(6):1357-9.
25. Guillevin L, Durand-Gasselin B, Cevallos R, et al. Microscopic polyangiitis: clinical and laboratory findings in eighty-five patients. Arthritis Rheum 1999;42(3):421-30.
26. Lauque D, Cadranel J, Lazor R, et al. Microscopic polyangiitis with alveolar hemorrhage. A study of 29 cases and review of the literature. Groupe d'Etudes et de Recherche sur les Maladies "Orphelines" Pulmonaires (GERM"O"P). Medicine (Baltimore) 2000;79(4):222-33.
27. Betensley AD, Yankaskas JR. Factor VIIa for alveolar hemorrhage in microscopic polyangiitis. Am J Respir Crit Care Med 2002;166(9):1291-2.
28. Swigris JJ, Fischer A, Gilles J, et al. Pulmonary and thrombotic manifestations of systemic lupus erythematosus. Chest 2008;133:271-80.
29. Abud-Mendoza C, Diaz-Jouanen E, Alarcon-Segovia D. Fatal pulmonary hemorrhage in systemic lupus erythematosus: occurrence without hemoptysis. J Rheumatol 1985;12:558-61.
30. Wiedemann HP, Matthay RA. Pulmonary manifestations of systemic lupus erythematosus. J Thorac Imaging 1992;7(2):1-18.
31. Nihoyannopoulos P, Gomez PM, Joshi J, et al. Cardiac abnormalities in systemic lupus erythematosus. Association with raised anticardiolipin antibodies. Circulation 1990;82(2): 369-75.
32. Rosenbaum E, Krebs E, Cohen M, et al. The spectrum of clinical manifestations, outcome and treatment of pericardial tamponade in patients with systemic lupus erythematosus: a retrospective study and literature review. Lupus 2009;18(7):608-12.
33. Tan EM, Cohen AS, Fries JF, et al. The 1982 revised criteria for the classification of systemic lupus erythematosus. Arthritis Rheum 1982;25:1271-7.
34. Hochberg MC. Updating the American College of Rheumatology revised criteria for the classification of systemic lupus erythematosus [letter]. Arthritis Rheum 1997;40:1725.
35. Louie S, Gamble CN, Cross CE. Penicillamine associated pulmonary hemorrhage. J Rheumatol 1986;13(5):963-6.
36. Haim DY, Lippmann ML, Goldberg SK, et al. The pulmonary complications of crack cocaine. A comprehensive review. Chest 1995;107(1):233-40.
37. Murray RJ, Smialek JE, Golle M, et al. Pulmonary artery medial hypertrophy in cocaine users without foreign particle microembolization. Chest 1989;96:1050-3.
38. Restrepo CS, Carrillo JA, Martínez S, et al. Pulmonary complications from cocaine and cocaine-based substances: imaging manifestations. Radiographics 2007;27(4):941-56.
39. Afessa B, Tefferi A, Litzow MR, et al. Diffuse alveolar hemorrhage in hematopoietic stem cell transplant recipients. Am J Respir Crit Care Med 2002;166(5):641-5.
40. Witte RJ, Gurney JW, Robbins RA, et al. Diffuse pulmonary alveolar hemorrhage after bone marrow transplantation: radiographic findings. Am J Roentgenol 1991;157:461-4.

41. Metcalf JP, Rennard SI, Reed EC, et al. Corticosteroids as adjunctive therapy for diffuse alveolar hemorrhage associated with bone marrow transplantation. University of Nebraska Medical Center Bone Marrow Transplant Group. Am J Med 1994;96(4):327-34.
42. Witte RJ, Gurney JW, Robbins RA, et al. Diffuse pulmonary alveolar hemorrhage after bone marrow transplantation: radiographic findings in 39 patients. Am J Roentgenol 1991;157 (3):461-4.
43. Frazier AA, Galvin JR, Franks TJ, et al. From the archives of the AFIP: pulmonary vasculature: hypertension and infarction. Radiographics 2000;20(2):491-524.
44. Primack SL, Miller RR, Müller NL. Diffuse pulmonary hemorrhage: clinical, pathologic, and imaging features. Am J Roentgenol 1995;164(2):295-300.
45. Gupta S, Jain A, Warneke CL, et al. Outcome of alveolar hemorrhage in hematopoietic stem cell transplant recipients. Bone Marrow Transplant 2007;40(1):71-8.
46. Saeed MM, Woo MS, MacLaughlin EF, et al. Prognosis in pediatric idiopathic pulmonary haemosiderosis. Chest 1999;116(3):721-5.
47. Phillip R, Luqmani R. Mortality in systemic vasculitis: a systematic review. Clin Exp Rheumatol 2008;26(5 suppl 51) S94-S104.